



The Effect of the Dental Operating Microscope on the Outcome of Nonsurgical Root Canal Treatment: A Retrospective Case-control Study

Navid Khalighinejad, DDS,* Anita Aminoshariae, DDS, MS,* James C. Kulild, DDS, MS,* Kristin A. Williams, DDS, MPH,[†] Jeannie Wang, DMD,* and Andre Mickel, DDS, MS*

Abstract

Introduction: The aim of the current investigation was to assess the effect of the use of a dental operating microscope on the outcome of nonsurgical root canal treatment (NS RCT) while treating the mesiobuccal (MB) root of the maxillary first molar. **Methods:** This retrospective investigation included endodontically treated maxillary first molars (ETMs) with apparent adequate previous NS RCT and restorations referred for endodontic retreatment at the endodontic graduate clinic. Inclusion criteria were ETMs that were diagnosed with irreversible pulpitis and normal periapical tissues before the initial NS RCT and ETMs that presented with a minimum of 1 identifiable periapical lesion (PAR) at 1 of the roots at the time of retreatment. One hundred ninety-five ETMs were included and divided into 2 groups: (1) the initial NS RCT had been performed using a microscope ($n = 83$) and (2) NS RCT had been performed without the use of a microscope ($n = 112$). Data extracted were whether the second MB (MB2) canal was located initially and the presence of an MB PAR at the time of retreatment. Data were statistically analyzed using binary logistic regression ($\alpha = 0.05$). **Results:** The MB root was 3 times more likely to present with a PAR at the time of retreatment if the initial NS RCT was performed without the use of a microscope ($P < .05$, odds ratio = 3.1). There was a significant association between a missed MB2 canal and an MB PAR in the group in which the initial NS RCT was performed without the use of a microscope ($P < .05$, odds ratio = 5.1). However, in cases in which the initial NS RCT was performed using a microscope, a missed MB2 canal was not associated with the presence of an MB PAR. **Conclusions:** With proper education, dentists can gain further insight into recognizing limitations in treating cases that require advanced training and advanced optics such as a microscope. Based on this strategy, it would appear that the outcome of NS RCT can be improved. (*J Endod* 2017;43:728–732)

An inability to locate and treat all the root canal systems (RCSs) is one of the factors that may lead to a nonhealing outcome after nonsurgical endodontic treatment (1).

The use of a dental operating microscope allows the detection of canals that have normally been difficult to recognize and treat in the absence of enhanced magnification (2, 3). The American Association of Endodontics suggests that all endodontists learn about the benefits of microscopes and incorporate the use of those devices in their practice (4).

Maxillary molars are the most endodontically treated posterior teeth and possess a complex root canal system (5). In *Colleagues for Excellence* (6) published by the American Association of Endodontics, the authors stated “as most maxillary first molars have two canals in the mesiobuccal (MB) root, case referral to endodontists for microscope-supported treatment should be considered.” However, a recent Cochrane systematic review reported that no study has investigated the effect of the microscope on the healing outcome of nonsurgical root canal treatment (NS RCT) (7).

Cross-sectional studies (8, 9) have reported that molars treated by endodontists using a microscope have significantly higher survival rates than molars treated by nonendodontists who did not use a microscope after 10 years. Also, Wolcott et al (10) suggested that a significant difference in the incidence of treated second MB (MB2) canals between initial NS RCT and any required retreatment may indicate that failure to find and treat existing MB2 RCSs will result in poorer healing outcomes. However, because of the use of nonpairwise comparison in the aforementioned studies, there were other confounding variables such as preoperative pulpal/periapical diagnoses, quality of the NS RCT, timing and quality of the postoperative restoration, and the presence of any systemic disease that could affect the outcome of NS RCT (11, 12). Therefore, the results of these studies (8–10) may not be representative of the effect of the use of a microscope or the presence of a missed MB2 canal on the healing outcome of NS RCT. If these conditions could be controlled, then an investigation could be performed to determine the difference in treatment outcomes performing NS RCT using a microscope.

To the best of our knowledge, no study has investigated the effect of the use of a microscope on the healing outcome of NS RCT (7). Therefore, the purpose of the present study was to assess the effect of the use of a microscope on the NS RCT healing outcome on the MB root of maxillary first molars.

Significance

With proper education, dentists can gain further insight into recognizing limitations in treating cases that require advanced training and advanced optics such as a dental operating microscope.

From the Departments of *Endodontics and [†]Public Health, Case Western Reserve University, School of Dental Medicine, Cleveland, Ohio.

Address requests for reprints to Dr Anita Aminoshariae, Case School of Dental Medicine, 2123 Abington Road A 280, Cleveland, OH 44106. E-mail address: Axa53@case.edu

0099-2399/\$ - see front matter

Copyright © 2017 American Association of Endodontists.

<http://dx.doi.org/10.1016/j.joen.2017.01.015>

Materials and Methods

The protocol of the present case-control study was approved by the Committee on Research Involving Human Subjects, Case Western Reserve University (CWRU), Cleveland, OH. Study data were collected and managed using General Systems Design Group academic data capture tools (Cedar Rapids, IA) hosted at CWRU.

Existing patients' electronic records based on the American Dental Association Code on Dental Procedures and Nomenclature identified all endodontically treated maxillary first molars (ETMs) with completely formed apices that exhibited nonhealing outcomes after the initial NS RCT and were referred for nonsurgical root canal retreatment at the graduate endodontic department between January 1, 2007, and January 1, 2016. A nonhealing outcome was defined as the presence of a minimum of 1 identifiable periapical lesion (PAR) on at least 1 of the roots (MB, distobuccal [DB], or palatal [P]) at the time of retreatment. This initial search resulted in 1045 ETMs from 1021 patients.

Patients' records, radiographs, and computerized databases were examined to identify samples that matched the inclusion criteria in the present study. Inclusion data for the ETMs were as follows:

1. Patients between 18 and 75 years of age in good health (American Society of Anesthesiologists classification I or II)
2. ETMs with an acceptable quality of the initial NS RCT according to the criteria suggested by Tronstad et al (13) and Farzaneh et al (14) (Table 1)
3. ETMs with preoperative digital radiographs before the initial NS RCT, preoperative radiographs before retreatment, and complete records with American Dental Association Code on Dental Procedures and Nomenclature treatment codes
4. ETMs with a pulpal diagnosis of irreversible pulpitis and normal apical tissues before the initial NS RCT
5. ETMs that received an adequate crown after the initial NS RCT that was confirmed by the absence of open/defective margins using a clinical and radiographic examination
6. Cases with a recorded date of the initial NS RCT and a time lapse between the initial NS RCT and referral for retreatment
7. Periodontally sound teeth or probing depths <5 mm with no bleeding
8. Teeth with no detectable crack(s); the presence or absence of a crown crack was confirmed during retreatment (all retreatments were performed under the microscope)
9. ETMs that presented with a minimum of 1 identifiable PAR associated with at least 1 of the roots (MB, DB, or P) at the time of retreatment
10. Restorable teeth with at least 2 mm of ferrule effect and at least 1 mm of dentinal thickness

TABLE 1. Suggested Criteria for Evaluating the Quality of Nonsurgical Root Canal Treatment (13, 14)

Radiographic parameter	Definition
Root canal obturation length	Adequate obturation: 0–2 mm short of the radiographic apex Short obturation: >2 mm from the radiographic apex Overextended obturation: beyond the radiographic apex
Void	Adequate: no voids present in obturation Root filling with visible voids

Teeth with no preoperative radiographs before the initial NS RCT, periodontally compromised teeth with a questionable prognosis, and cases with suspected vertical root fracture (15) were excluded. Also, ETMs with any operative mishaps such as a perforation and/or a separated file were excluded. ETMs that were obturated with a material other than gutta-percha were excluded.

Two independent reviewers (N.K. and J.W.) who were blind regarding whether the initial NS RCT was performed using a microscope or not evaluated the radiographs of the ETMs, which were taken before retreatment. The periapical status was assessed according to Lopez-Lopez et al's study (16) using the periapical index (PAI) described by Orstavik et al (17). Based on the scoring system, PAI ≥3 was considered to be a sign of periapical pathology. Before evaluation, the observers were calibrated regarding the PAI system. These patients were randomly selected. The interobserver agreement test on the PAI scores on the 50 patients produced a Cohen kappa of 0.82.

Screening of the ETMs that met the inclusion criteria yielded 195 ETMs, from which 195 patients were included in the final analysis to avoid clustering effects. This considered a PAR at a single level as an independent entity, which reduced the effect of patients as a risk factor (18). The following data were collected from the included patients' records by 2 blinded reviewers (N.K. and J.W.) regarding whether the initial NS RCT was performed using a microscope or not:

1. Patient-related factors: age and sex
2. Whether the MB2 canal was identified and treated during the initial NS RCT. This was later confirmed using a microscope during retreatment. This variable was dichotomized as present or absent for each sample for statistical analysis.
3. The presence of a PAR on the MB root was assessed and dichotomized as present or absent and used as the dependent variable. Also, the presence of a PAR on the DB and P roots was assessed.

After data collection, included ETMs were then divided into 2 groups:

1. Patients who received the initial NS RCT at the endodontic department using a microscope and referred back for the retreatment (microscope group, *n* = 83)
2. Patients who received the initial NS RCT without the use of a microscope by general dentists at a dental clinic and were referred for retreatment (nonmicroscope group, *n* = 112)

TABLE 2. Distribution and Characteristics of Included Endodontically Treated Maxillary First Molars

Characteristics	DOM group, <i>n</i> = 83 (43%)	Non-DOM group, <i>n</i> = 112 (57%)	<i>P</i> value (chi-square and <i>t</i> test)
Age	54	43	.75
Sex, <i>n</i> (%)			
Male	48 (58)	66 (59)	.11
Female	35 (42)	46 (41)	
Time lapse between the initial NS RCT and retreatment (y)	5.5	2.6	.02*
Identified MB2 canal in the initial NS RCT, <i>n</i> (%)	51 (62)	21 (19)	.02*
MB root lesion at the time of retreatment, <i>n</i> (%)	21 (26)	82 (73)	.01*

DOM, dental operating microscope; MB, mesiobuccal; MB2, second mesiobuccal; NS RCT, nonsurgical root canal treatment.

*The significance level is *P* = .05.

TABLE 3. Binary Logistic Regression Model with the Pooled Odds Ratio of Presence of Lesion on the Mesio Buccal Root as the Dependent Variable

Covariates	Odds ratio (95% CI)	P value
Age	1.1 (0.76–5.23)	.66
Sex	0.7 (0.1–4.6)	.1
Use of DOM in the initial NS RCT	3.1 (1.79–8.43)	.01
Initial NS RCT performed without DOM (odds are compared with the use of DOM)		
Treatment of MB2 canal in the initial NS RCT	2.04 (1.43–5.65)	.021*
Untreated MB2 canal in the initial NS RCT (odds are compared with treated MB2 canal)		

CI, confidence interval; DOM, dental operating microscope; MB2, second mesio buccal; NS RCT, nonsurgical root canal treatment.

*Significance level is $P = .05$.

Statistical analysis was performed using the Statistical Package for the Social Sciences software Version 18.0 (SPSS Inc, Chicago, IL). The frequency distributions of all the parameters were obtained. To determine the association between various parameters, a Pearson chi-square test was performed. To analyze the correlation between independent variables such as the use of a microscope and the presence of an MB2 canal and the presence of apical periodontitis at the MB root (dependent variable), binary logistic regression analysis was performed to determine the odds ratio (OR) after controlling confounding variables at a significance level of .05.

Results

Characteristics of ETMs Referred for Nonsurgical Root Canal Retreatment

In the present study, 195 teeth from 195 individuals (male = 51.6%, female = 48.4%) with a mean age of 48 years were included for analysis. Of the 195 included teeth, 83 teeth had received the initial NS RCT at the CWRU endodontic department using a microscope (microscope group), and 112 teeth received the initial NS RCT by general dentists at a dental clinic without the use of a microscope (nonmicroscope group). There was no significant difference between the 2 groups regarding sex and age ($P > .05$). The mean time between the initial NS RCT and retreatment was 5.5 and 2.6 years for the microscope and nonmicroscope groups, respectively. Table 2 details the distribution and characteristics of the included teeth.

In 62% of the ETMs in the microscope group, the MB2 canal was located during the NS RCT. However, only in 19% of ETMs in the

nonmicroscope group was the MB2 canal located. There was a significant association between the use of a microscope and identification of the MB2 canal ($P = .02$, OR = 3.38). Twenty-six percent of the ETMs showed a PAR on the MB root at the time of retreatment in the microscope group. This rate was 73% for the nonmicroscope group. The crude OR revealed that there was a significant association between the use of a microscope in the initial NS RCT and the presence of a lesion on the MB root at the time of retreatment ($P = .01$, OR = 3.8). However, there was no significant association between the use of a microscope and the presence of either a DB or P lesion ($P > .05$).

Regression Models for the “Presence of a Lesion on the MB Root” as the Dependent Variable

The results were further analyzed in binary logistic regression models with the odds of “presence of lesion” as the dependent variable in different models for the presence of a lesion on the MB, DB, and P roots (Table 3). Causal pathway modeling predicts the presence of a PAR on the MB root at the time of retreatment. In this model, the MB2 RCS lies in the causal pathway of the model (Fig. 1). There was no significant association between patient-related factors such as sex, age, and the presence of a lesion on any of the roots ($P > .05$).

Based on the regression analysis with the presence of an MB lesion at the time of retreatment as a dependent variable, it would appear that there was a significant association between the use of a microscope in the initial NS RCT and the presence of an MB lesion at the time of retreatment controlling the covariates (Table 4). The MB root of maxillary first molars was 3 times more likely to present with a lesion at the time of retreatment if the initial NS RCT was performed without the use of a microscope ($P = .01$, OR = 3.1). Furthermore, the effect of a missed MB2 canal in the initial NS RCT as an independent variable was assessed on the presence of an MB lesion at the time of retreatment. A missed MB2 canal in the initial NS RCT was significantly associated with the presence of an MB lesion at the time of retreatment. ETMs with a previously missed MB2 canal at the time of the initial NS RCT were 2.04 times more likely to present with an MB PAR at the time of retreatment ($P = .021$, OR = 2.04). Data were stratified based on the use of a microscope in the initial NS RCT. According to the stratified OR, a missed MB2 canal was significantly associated with the presence of a PAR on the MB root in the group in which the initial NS RCT was not performed under a microscope ($P = .02$, OR = 5.1). However, in the group in which the initial NS RCT was performed under a microscope, there was no significant association between a missed MB2 canal and an MB PAR ($P = .12$).

In regression models with DB and P lesions as dependent variables, there was no significant association between the presence of a PAR on DB or P roots and the use of a microscope in the initial NS RCT.

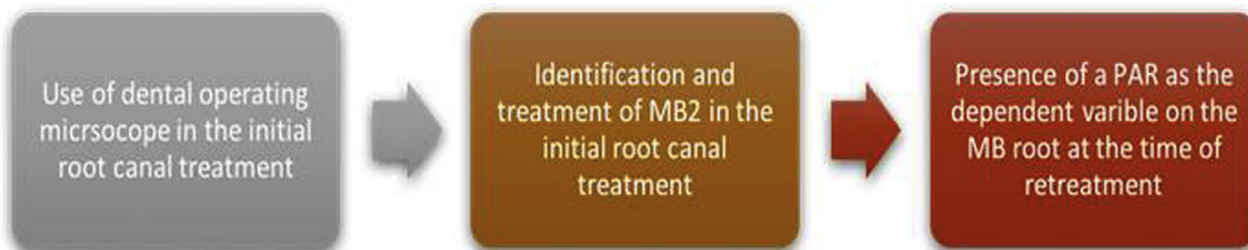


Figure 1. Causal pathway modeling of the effect of use of a dental operating microscope in the initial root canal treatment on the presence of a PAR on the MB root at the time of retreatment.

TABLE 4. Stratified Odds Ratio with the Odds of the Presence of a Lesion on the Mesio Buccal Root as the Dependent Variable

Independent variable	DOM group		Non-DOM group	
	Odds ratio (95% CI)	P value	Odds ratio (95% CI)	P value
Treatment of MB2 canal in the initial NS RCT Untreated MB2 canal in the initial NS RCT (odds are compared with treated MB2)	1.45 (1.11–6.43)	.12	5.1 (3.21–8.78)	.02*

CI, confidence interval; DOM, dental operating microscope; MB2, second mesiobuccal; NS RCT, nonsurgical root canal treatment.

*Significance level is $P = .05$.

Discussion

The authors assessed the effect of the use of a microscope on the outcome of NS RCT regarding the MB root, controlling for confounding variables. The MB root of maxillary first molars was selected because of its complexity and high probability of the presence of a second RCS (10). We suggest that this added complexity could highlight the effect of a microscope on the outcome of NS RCT. The results of this investigation report that MB roots of maxillary first molars are 3 times more likely to present with a PAR at the time of retreatment if the initial NS RCT was performed without the use of a microscope. Also, none of the patient-related factors such as sex and age affected the outcome of NS RCT, which is consistent with previous studies (19, 20).

Different pre-, intra-, and postoperative factors have been associated with the outcome of NS RCT (12). Following strict inclusion and exclusion criteria, this study tried to minimize the effect of confounders. All included samples in both microscope and nonmicroscope groups were diagnosed with irreversible pulpitis before the initial NS RCT. This controlled for the effect of preoperative diagnosis as being 1 of the factors that affect the outcome (12). To control for the effect of root canal quality as an intraoperative factor, all included ETMs showed adequate quality of NS RCT (13, 14, 21). Postoperatively, all included teeth had been restored with adequate crowns with satisfactory margins to control for the effect of postoperative restoration on the outcome of NS RCT (22).

The present study reported that ETMs were 3 times more likely to present with a PAR at the time of retreatment if the initial NS RCT was performed without the use of a microscope. This finding may show that the use of a microscope could significantly improve the outcome of NS RCT in roots with anatomic complexity, such as the MB root of the maxillary first molar. These findings are in agreement with Burry et al (8), who reported that “molars treated by endodontists after 10 years have significantly higher survival rates than molars treated by non-endodontists.” However, in Burry et al’s study, outcome was defined as survival, and the main reason for the difference in the survival rate was not elucidated because of nonpairwise comparison.

Failure to locate and treat existing MB2 RCSs has been associated with the poor long-term healing outcomes. Wolcott et al (10) suggested that the “significant difference in the incidence of a MB2 canal between initial treatments and retreatments might indicate that failure to find and treat existing MB2 canals will decrease the long-term prognosis.” However, the cross-sectional nature of that study did not control the effect of various confounding variables that are known to affect the outcome of NS RCT. Hence, it is not reasonable to conclude from Wolcott et al (10) that failure to treat existing MB2 canals could affect the outcome of NS RCT. The current investigation showed, for the first time, that maxillary first molars that received NS RCT without the use of a microscope are almost 5 times more likely to develop a PAR on the MB root if an MB2 RCS had not been identified and treated. However, in the cases in which NS RCT was performed using a microscope, a missed MB2 canal was not associated with the healing outcome of NS RCT on the MB

root. These findings could be a good indicator of why cases with complexity need to be treated using a microscope.

Based on the findings of the present study, the use of a microscope may improve the outcome of NS RCT in cases with anatomic complexity. It is worth mentioning that the time lapse between the initial NS RCT and a definitive restoration was not clear for the specimens in the current study. Considering the fact that this time lapse may have potentially negatively affected the outcome of the NS RCT (22), this variable should be controlled in future studies. A microscope may help endodontists identify RCSs that would have otherwise remained unidentified and reduce the healing outcome. It should be emphasized that, in order to draw a relationship between the use of a microscope and a positive healing outcome, further prospective cohort studies should be performed. It should also be acknowledged that the results are based on the patients who returned and were referred for nonsurgical root canal treatment. With proper education, general dentists can gain further insight into recognizing limitations in treating cases that require advanced training and the use of a microscope. This strategy may improve the healing outcome of NS RCT and retreatment in cases with significant challenges.

Acknowledgments

The authors deny any conflicts of interest related to this study.

References

- Song M, Kim HC, Lee W, Kim E. Analysis of the cause of failure in nonsurgical endodontic treatment by microscopic inspection during endodontic microsurgery. *J Endod* 2011;37:1516–9.
- Rampado ME, Tjaderhane L, Friedman S, Hamstra SJ. The benefit of operating microscope for access cavity preparation by undergraduate students. *J Endod* 2004;30:863–7.
- Coelho de Carvalho MC, Zuolo ML. Orifice locating with a microscope. *J Endod* 2000;26:532–4.
- American Association of Endodontists. *AAE position statement on use of microscopes and other magnification techniques*. Available at: www.aae.org. Accessed September 4, 2016.
- Pretzl B, Eickholz P, Saure D. Endodontic status and retention of molars in periodontally treated patients: results after 10 or more years of supportive periodontal therapy. *J Clin Periodontol* 2016;43:1116–23.
- Available at: <http://www.aae.org/publications-and-research/endodontics-colleagues-for-excellence-newsletter/canal-preparation-and-obturation-an-updated-view-of-the-two-pillars-of-nonsurgical-endodontics.aspx>. Accessed September 4, 2016.
- Del Fabbro M, Taschieri S, Lodi G, et al. Magnification devices for endodontic therapy. *Cochrane Database Syst Rev* 2015;12:CD005969.
- Burry JC, Stover S, Eichmiller F, Bhagavatula P. Outcomes of primary endodontic therapy provided by endodontic specialists compared with other providers. *J Endod* 2016;42:702–5.
- Alley BS, Gray Kitchens G, Alley LW, Eleazer PD. A comparison of survival of teeth following endodontic treatment performed by general dentists or by specialists. *Oral Surg Oral Med Oral Pathol Oral Radiol Endod* 2004;98:115–8.
- Wolcott J, Ishley D, Kennedy W, et al. A 5 yr clinical investigation of second mesiobuccal canals in endodontically treated and retreated maxillary molars. *J Endod* 2005;31:262–4.
- Salehrabi R, Rotstein I. Endodontic treatment outcomes in a large patient population in the USA: an epidemiological study. *J Endod* 2004;30:846–50.

12. Ng YL, Mann V, Gulabivala K. Tooth survival following non-surgical root canal treatment: a systematic review of the literature. *Int Endod J* 2010;43:171–89.
13. Tronstad L, Asbjornsen K, Doving L, et al. Influence of coronal restorations on the periapical health of endodontically treated teeth. *Endod Dent Traumatol* 2000;16:218–21.
14. Farzaneh M, Abitbol S, Friedman S. Treatment outcome in endodontics: the Toronto study. Phases I and II: orthograde retreatment. *J Endod* 2004;30:627–33.
15. PradeepKumar AR, Shemesh H, Jothilatha S. Diagnosis of vertical root fractures in restored endodontically treated teeth: a time-dependent retrospective cohort study. *J Endod* 2016;42:1175–80.
16. Lopez-Lopez J, Jane-Salas E, Estrugo-Devesa A, et al. Periapical and endodontic status of type 2 diabetic patients in Catalonia, Spain: a cross-sectional study. *J Endod* 2011;37:598–601.
17. Orstavik D, Kerekes K, Eriksen HM. The periapical index: a scoring system for radiographic assessment of apical periodontitis. *Endod Dent Traumatol* 1986;2:20–34.
18. Aarts E, Verhage M, Veenliet JV, et al. A solution to dependency: using multilevel analysis to accommodate nested data. *Nat Neurosci* 2014;17:491–6.
19. Nagasiri R, Chitmongkolsuk S. Long-term survival of endodontically treated molars without crown coverage: a retrospective cohort study. *J Prosthet Dent* 2005;93:164–70.
20. Caplan DJ, Weintraub JA. Factors related to loss of root canal filled teeth. *J Public Health Dent* 1997;57:31–9.
21. Gillen BM, Looney SW, Gu LS, et al. Impact of the quality of coronal restoration versus the quality of root canal fillings on success of root canal treatment: a systematic review and meta-analysis. *J Endod* 2011;37:895–902.
22. Pratt I, Aminoshariae A, Montagnese TA, et al. Eight-year retrospective study of the critical time lapse between root canal completion and crown placement: its influence on the survival of endodontically treated teeth. *J Endod* 2016;42:1598–603.